

# Detection and successful treatment of emergent anti-SSA—mediated fetal atrioventricular block



**BACKGROUND:** Fetal complete atrioventricular block occurs between 18 and 26 weeks in 2–4% of anti-SSA-positive pregnancies, but disease burden is considerable: Eighteen percent die in utero or before the age of 2 years, and survivors ultimately require permanent cardiac pacing.<sup>1</sup> Reports suggest that as the fetal rhythm transitions from normal to complete atrioventricular block, antiinflammatory treatment can improve atrioventricular conduction and even restore sinus rhythm.<sup>2,3</sup> Little is known about this transition period of emergent complete atrioventricular block, and to date, surveillance methods have unsuccessfully detected emergent complete atrioventricular block in time for effective in utero treatment.<sup>4</sup>

**OBJECTIVE:** The objectives of the study were to describe the transition times from normal fetal rhythm to emergent complete atrioventricular block and from emergent complete atrioventricular block to complete atrioventricular block and to describe long- and short-term results of in utero treatment of emergent complete atrioventricular block.

**STUDY DESIGN:** This was an observational case series of 4 anti-SSA-positive pregnancies (3 with a previous complete atrioventricular block fetus) that developed fetal emergent complete atrioventricular block at 19–20 weeks of gestation. One was not undergoing surveillance, 3 participated in weekly surveillance echocardiograms<sup>4</sup> from 16–17 to 26 weeks, and 2 of 3 assessed fetal rhythm 2 times per day using a commercially available Doppler device. Irregular fetal rhythm, or a rate of <100 bpm, prompted immediate diagnostic echo. Mothers were given intravenous immune globulin and/or oral dexamethasone for surveillance or diagnostic echo findings of fetal emergent complete atrioventricular block.

**RESULTS:** In subjects 1 and 2 (Figure 1, A and B), emergent complete atrioventricular block was detected in time for treatment to restore 1:1 AV conduction. An irregular fetal heart rate was detected in subject 1 during home Doppler monitoring 8 hours after hearing a regular rhythm. Subject 2's 20 week surveillance fetal echo showed atrioventricular intervals of 120–230 ms. Both received dexamethasone and intravenous immune globulin and were in sinus rhythm within 3–7 days. Dexamethasone (tapered from 4 mg/d over 1 month) was continued until 32 weeks (subject 2) or birth (subject 1). Both neonates had 1:1 conduction and prolonged PR intervals, which have persisted for 4 and 2 years, respectively. Neither is paced. In subjects 3 and 4

(Figure 1C), emergent complete atrioventricular block was either not recognized in time for successful treatment or in utero treatment was successful but discontinued before 28 weeks. An irregular fetal heart rate was detected in subject 3 during home Doppler monitoring at 19 4/7 weeks, 12 hours after hearing a normal rhythm, but the subject did not seek medical attention. Twelve hours later (24 hours after the last normal rhythm), the fetus was in complete atrioventricular block and did not respond to intravenous immune globulin and dexamethasone. Subject 4 was diagnosed at 19 weeks with emergent complete atrioventricular block and responded to dexamethasone with restored 1:1 conduction, but dexamethasone was discontinued (24 weeks) and emergent complete atrioventricular block recurred at 26 weeks and was not treated. Both subjects were in complete atrioventricular block at birth, and both are paced and are doing well at 4 years of age.

**CONCLUSION:** The following conclusions were reached: (1) the transition from normal rhythm to emergent complete atrioventricular block and from emergent complete atrioventricular block to complete atrioventricular block occurs in <24 hours; (2) treatment of emergent complete atrioventricular block can restore 1:1 conduction; and (3) treatment beyond 24 weeks may be necessary to maintain 1:1 conduction at least until birth. These findings suggest daily surveillance of fetal rhythm is necessary to detect emergent complete atrioventricular block and institute successful treatment. ■

Bettina F. Cuneo, MD  
Institute for Maternal and Fetal Health and the Heart Institute  
Children's Hospital Colorado  
The University of Colorado School of Medicine  
Aurora, CO  
[bettina.cuneo@childrenscolorado.org](mailto:bettina.cuneo@childrenscolorado.org)

Steven E. Ambrose, MD  
Advocate Christ Hospital  
Chicago, IL

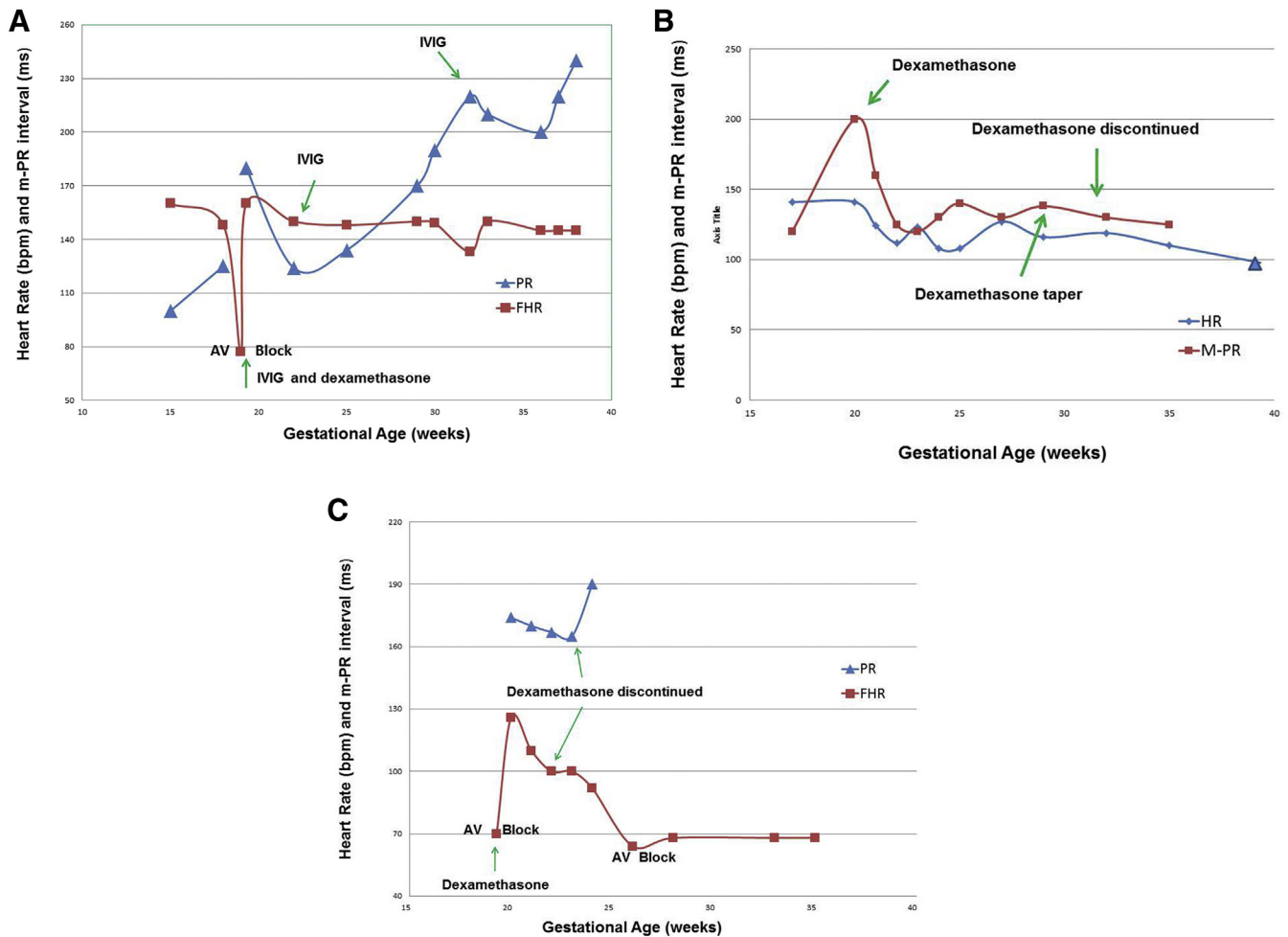
Wayne Tworetzky, MD  
Department of Pediatrics  
Section of Cardiology  
Boston Children's Hospital  
Harvard Medical School  
Boston, MA

The authors report no conflict of interest.

## REFERENCES

1. Izmirly PM, Saxena A, Kim MY, et al. Maternal and fetal factors associated with mortality and morbidity. *Circulation* 2011;124:1927-35.

**FIGURE**  
Fetal heart rate and m-PR interval graphed against gestational age



Treatments are indicated by arrows. **A**, Subject 1. **B**, Subject 2. **C**, Subject 3.

AV, atrioventricular; FHR, fetal heart rate; IVIG, intravenous immune globulin; M-PR, mechanical PR interval; PR, interval between P-wave and R-wave on electrocardiogram. Cuneo. Detection and treatment of anti-SSA mediated emergent CAVB. *Am J Obstet Gynecol* 2016.

2. Askanase AD, Friedman DM, Copel J. Spectrum and progression of conduction abnormalities in infants born to mothers with anti-SSA/Ro/SSB-La antibodies. *Lupus* 2002;11:145-51.  
 3. Eliasson H, Sonesson SE, Sharland G, et al. Isolated atrioventricular block in the fetus: a retrospective, multinational, multicenter study of 175 patients. *Circulation* 2011;24:1919-26.

4. Friedman DM, Kim MY, Copel JA, et al. Utility of cardiac monitoring in fetuses at risk for congenital heart block: the PR Interval and Dexamethasone Evaluation (PRIDE) prospective study. *Circulation* 2008;117:485-93.

© 2016 Elsevier Inc. All rights reserved. <http://dx.doi.org/10.1016/j.ajog.2016.07.002>

## Poor compliance and lack of improvement in birth certificate reporting of assisted reproductive technology pregnancies in the United States



**INTRODUCTION:** Since 1900 the birth certificate has been a valuable source of information regarding pregnancy outcomes in the United States.<sup>1</sup> In 2003, the US Standard Certificate of

Live Birth was modified to include information regarding infertility treatments leading to conception. These include assisted reproductive technologies (ART) such as in vitro